

# Periodontal Plastic Surgery Framework for the Perfect Smile



Cosmetic surgery has become more popular than ever before especially now that more Americans are living longer and aging more gracefully with the help of plastic surgery. The American Society for Aesthetic Plastic Surgery (ASAPS) reports there were nearly 8.5 million cosmetic surgical and nonsurgical procedures performed in 2001,<sup>1</sup> which represents a 48 percent increase over 2000. Furthermore, the ASAPS found a 304 percent increase from 1997-2001.

Periodontal plastic surgery has also felt this trend as it has experienced a significant shift toward cosmetic-related surgery to enhance smiles. Through resective and augmentation therapy, periodontists can help make your smile last a lifetime.

A recent poll of 253 consumers conducted by the American Academy of Periodontology found the following:<sup>2</sup>

- 50 percent consider the smile the first facial feature they notice
- 80.49 percent are not happy with their smile
- Respondents were seven times more likely to have periodontal, smile enhancement procedures, than face-lifts
- Smile enhancement procedures outnumbered eyelid surgeries five to one

<sup>1</sup> The American Society for Aesthetic Plastic Surgery 2001 Cosmetic Surgery Statistics Quick Facts. [http://surgery.org/news\\_releases/feb2002quickfacts.html](http://surgery.org/news_releases/feb2002quickfacts.html)

Periodontal Plastic Surgery Framework for the Perfect Smile <sup>2</sup> The American Academy of Periodontology Consumer Esthetics Survey, March 2002



# Crown Lengthening

Crown lengthening is a procedure to remove the excess gum tissue, exposing more of the “crown” of the tooth. The gum line is then sculpted (or sutured) to create the right proportion between gum tissue and tooth surface. This sets the stage, allowing your new veneers or crowns to have the correct length and shape.

## Reasons for Crown Lengthening

This procedure is for patients who feel their teeth are too short (known as a gummy smile) or their gum line is uneven.

# Crown Lengthening



## Gummy Smile

A 13-year-old girl has excessive gingival overgrowth (a gummy smile) due to orthodontics.

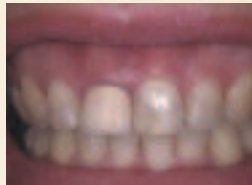

Eighteen months after crown lengthening procedure.



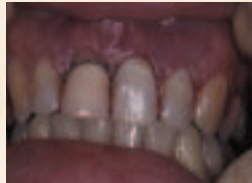Four years after crown lengthening procedure.

Photos by CL Townsend, D.D.S.

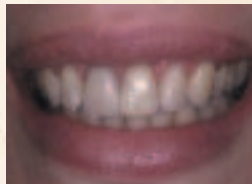

## Wedding

A patient wanted to improve the appearance of her crown to enhance her smile prior to her wedding.

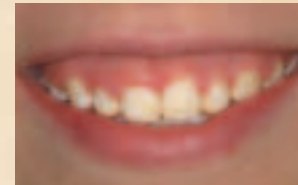

A minimally invasive microsurgical technique was used to reshape the bone support and to achieve symmetrical crown lengths.



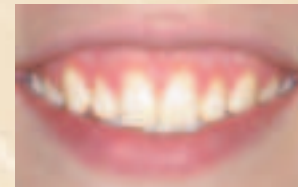Results after crown lengthening and a new crown.

Photos by BL Butler, D.D.S. and T Bridgeman, D.D.S.



## Postorthodontic

After orthodontic treatment, the patient's teeth appear to slope down to the right and her lower lip appears asymmetrical.



Two months after treatment tooth length and symmetry are improved.

Photos by CL Townsend, D.D.S.

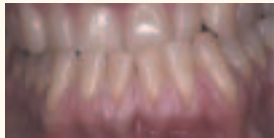# Root Coverage

During this procedure, gum tissue from your palate or other materials are used to facilitate coverage of the exposed root. This can be done for one tooth or several teeth to even your gum line and reduce sensitivity.

## Reasons for Root Coverage

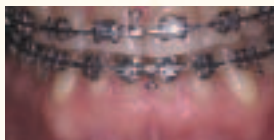
Soft tissue grafts can be used to cover roots, develop gum tissue where absent due to excessive gingival recession or to make prosthetic devices, such as dental implants, look natural. In some cases, they can cover exposed roots to protect them from decay and prepare teeth for orthodontic treatment. This may reduce tooth sensitivity and improve the esthetics of your smile as well.

# Root Coverage

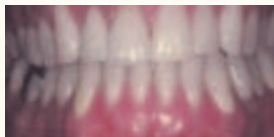


## Orthodontics

Root coverage will enhance this patient's smile and thicken his gums, decreasing the risk of recession during orthodontic treatment.

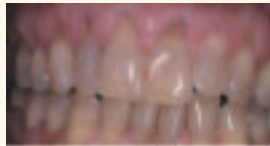

Root coverage was completed in one surgery with a gingival graft and the patient underwent orthodontic therapy three months later.



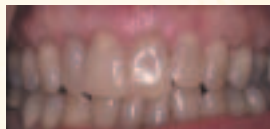Photos by BL Butler, D.D.S.

Final results after periodontal treatment and orthodontic therapy.



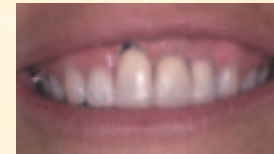## Exposed Roots

This patient wanted to improve her smile.



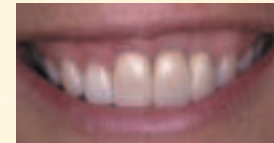Photos by BL Butler, D.D.S.

Root coverage was achieved as well as a significant thickening of the gums, which decreases her risk of obtaining periodontal diseases.



## Dental Implant

This patient's front dental implant was partially exposed, creating an undesirable smile.



Photos by BL Butler, D.D.S.

A gingival graft was placed to cover the exposed implant so the restorations did not need to be replaced.

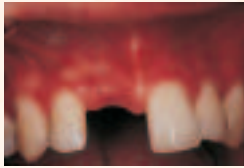# Dental Implants

A dental implant is an artificial tooth root placed into the jaw to hold a replacement tooth or bridge in place, or to provide support for a denture.

## Reasons for Dental Implants

Dental implants are the answer for many people with missing or damaged teeth – they look and feel just like your own teeth. Implants enhance smiles and prevent bone loss that often accompanies dentures.

# Dental Implants



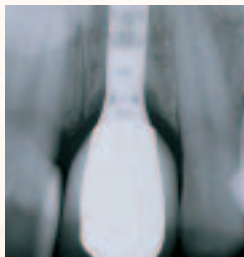
## Dental Implant

This patient lost her front tooth and did not want traditional bridgework.



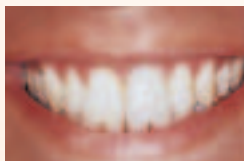
The dental implant is indistinguishable from the natural tooth. The patient can smile, speak, and eat again with comfort and confidence.

Photos by BL Butler, D.D.S. and T Butson, D.D.S.

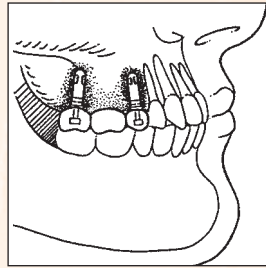


## X-ray of Implant

This dental implant was successfully fused to the jawbone and covered with a crown to provide natural-looking teeth.

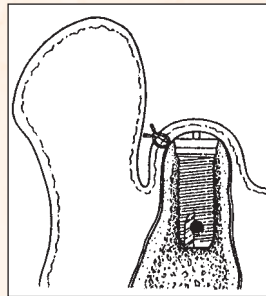


Photos by BL Butler, D.D.S. and C Suzuki, D.D.S.

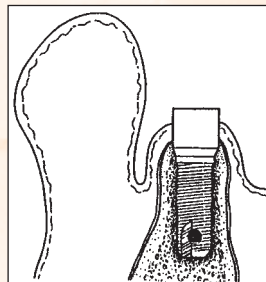


## Implant Placement Procedure

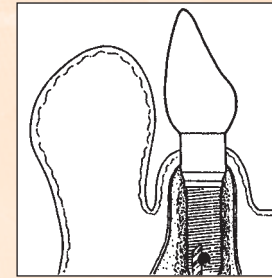
1: Dental implants can support a fixed bridge, eliminating the need for a removable partial denture.



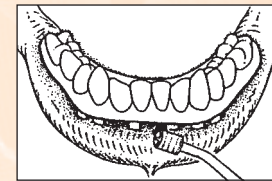
2: Implants are placed into the jawbone. After this surgical treatment, the bone in the jaw attaches to the implants, holding them firmly in place. The attachment of bone to the implant usually takes three to six months.



3: Small posts are attached to the implant, projecting through the gums. Several weeks after this second procedure the replacement crown can be fabricated.



4: Replacement teeth are created and securely attached to the small posts.



5: After treatment is complete, brushing, flossing and regular professional dental care are essential to the success of the dental implant.

Source: American Academy of Periodontology

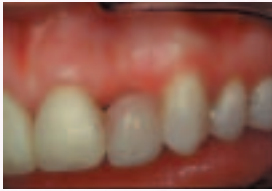# Ridge Augmentation

Ridge augmentation procedures are used to correct concavities in the jawbone where natural teeth are missing.

## Reasons for Ridge Augmentation

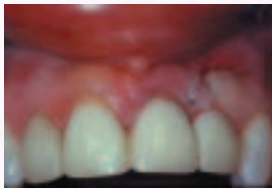
Ridge augmentation corrects depressions in your gum line that are unnatural looking and sometimes make you seem older than you really are. It is also used to prevent the jawbone from collapsing following tooth extraction, and helps to even out replacement teeth that may seem too long compared to adjacent teeth.

# Ridge Augmentation

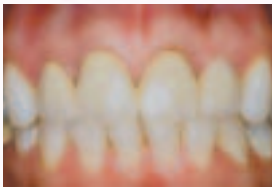

## Asymmetrical Bridge

This patient had a fixed bridge and one of the teeth became asymmetrical due to a concavity of his jawbone.

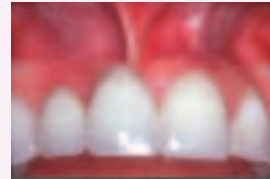

A connective tissue ridge augmentation procedure was performed to repair the concavity.



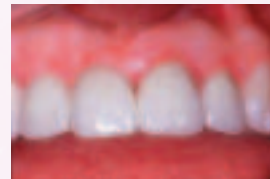Ridge augmentation builds up the jawbone, giving the fixed bridge a more natural look.

Photos by CL Townsend, D.D.S. and S Carstensen, D.D.S.



## Ridge Deficiency

This patient has a significant gum deficiency and the adjacent teeth have porcelain extensions to create symmetry with the abnormally long two front teeth.



Photos by CL Townsend, D.D.S.

A new bridge with completely revised teeth lengths after ridge augmentation created a much enhanced gum profile.


# Combination Procedures

A combination of periodontal procedures can result in a beautiful new smile and improved periodontal health – your keys to smiling, eating, and speaking with comfort and confidence.

## Reasons for Combination Procedures

Your periodontist may use several different types of procedures to build a framework for your perfect smile. Oftentimes, periodontal plastic surgery lays the foundation for further cosmetic enhancements by your general dentist.

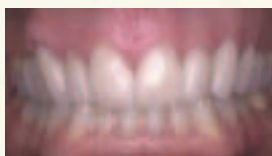# Combination Procedures



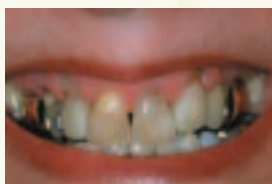## Veneers

(root coverage/  
crown lengthening)

This patient wanted an even gum line before getting veneers. The combination of procedures helped to achieve this goal.

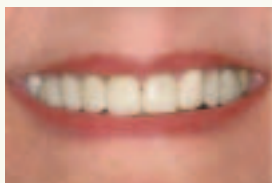


Photos by BL Butler, D.D.S. and G Chyz, D.D.S.

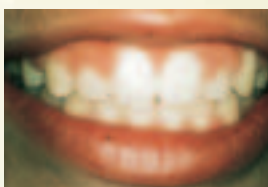


## Groundwork for a Perfect Smile

A combination of augmentation, resective therapy, and restorative procedures created this greatly improved smile.

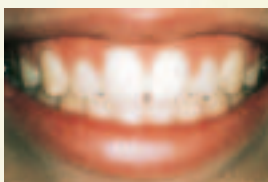


Photos by CL Townsend, D.D.S. and L Jones, D.D.S.




## Orthodontics

After orthodontic treatment, this patient wanted an even smile.




Photos by CL Townsend, D.D.S.

Final results show the success of root coverage and crown lengthening procedures.



## Girlish Smile

These full face before and after photos illustrate there are different tooth shapes and also different types of faces and smiles. A gingival graft and crown lengthening helped improved this young lady's "girlish smile."



Photos by CL Townsend, D.D.S.