

PRINCIPLES AND PRACTICE OF PERIODONTAL MICROSURGERY

Leonard S. Tibbetts, DDS, MSD¹
Dennis Shanelec, DDS²

Periodontal microsurgery is the refinement of basic surgical techniques made possible by the improved visual acuity gained with the use of the surgical microscope. In the hands of a trained and experienced clinician, microsurgery offers enhanced outcomes not possible with traditional macrosurgery, especially in terms of passive wound closure and reduced tissue trauma. This paper aims to briefly review the basics of periodontal microsurgery, including the role and instruments of magnification, hand positions, knot tying, clinical applications, and microsurgery's effect on esthetics. The improved visual acuity of microsurgery provides significant advantages to those who take the time to become proficient in microsurgical principles and procedures. *INT J MICRODENT* 2009;1:13-24

In the minds of many dental professionals, microsurgery is an interesting concept, and yet the inability of most clinicians to perform such procedures shows the dental profession's lack of understanding of what microsurgery truly encompasses. Dentistry has borrowed microscopic surgery from medicine, which dates back to 1922.^{1,2} It behooves dentistry to piggyback on medical experience, rather than rediscover it. The purpose of this paper is to provide a brief review of what periodontal microsurgery entails: the role of magnification, microsurgical instrumentation and design, the surgeon's physiologic and physical status, posture, hand positions, knot tying, appropriate applications, and the effects of microsurgery on esthetics.

Periodontal microsurgery³ is the refinement of basic surgical techniques made possible by the improvement in visual acuity gained with the use of the surgical microscope. In 1979, Daniel¹ defined microsurgery in broad terms as surgery performed under magnification by the microscope. In 1980, microsurgery was described by Serafin⁴

as a methodology—a modification and refinement of existing surgical techniques using magnification to improve visualization, with applications to all specialties. Regardless of whether they are dentists, physicians, or veterinarians, all reconstructive surgeons have the ability to use visually enhanced surgical techniques.

As a treatment philosophy, microsurgery incorporates three important principles⁵:

1. Improvement of motor skills, thereby enhancing surgical ability
2. An emphasis on passive wound closure with exact primary apposition of the wound edge
3. The application of microsurgical instrumentation and suturing to reduce tissue trauma

Most dental treatment, historically, has been rendered with the unaided eye. Without the use of visual magnification, such treatment is termed macroscopic. Treatment rendered with visual enhancement supplied by the microscope is termed microscopic. Improved outcomes obtained from the use of microscopic

¹Private practice, Arlington, Texas.

²Private practice, Santa Barbara, California.

Correspondence to:

Dr Leonard S. Tibbetts
916 West Mitchell Street
Arlington, TX 76016
Fax: 817 274 0872
Email: lstibbetts@sbcglobal.net

periodontal surgical procedures have resulted in a shift toward periodontal microsurgery. Over the past two decades, periodontics has seen increasing refinement of surgical procedures, requiring the development of more intricate surgical and motor skills. The techniques used in periodontal plastic surgery, guided tissue regeneration, cosmetic restorative crown lengthening, gingival augmentation procedures, soft and hard tissue ridge augmentation, osseous resection, and dental implant placement demand clinical expertise beyond the range of normal visual acuity.

Microsurgery represents an amplification of universally recognized surgical principles in which gentle handling of soft and hard tissues and extremely accurate wound closure are made possible through magnification, allowing for well-planned and precisely executed surgical procedures.⁶ The goal of the periodontist is to cause as little damage as possible to tissues and to have healing occur by primary rather than secondary intention. Healing by secondary intention occurs when the wound edges open and heal more slowly and with more inflammation as granulation tissue fills the wound. Microsurgery offers a more rapid and comfortable healing phase for the patient.

CLINICAL PHILOSOPHY

Consistent application of the philosophy and techniques learned in basic microsurgery education is necessary for the operator to attain a level of experience and competence needed for various periodontal surgical procedures.⁵ Effective periodontal microsurgery allows the operator to consistently achieve clinical results that were once thought to be unlikely. Becoming a clinically proficient periodontal microsurgeon requires a willingness to adopt new values and ideas. Training with the microscope enhances the motor skills, which can translate to improved surgical skills. The methods of precise, deli-

cate tissue handling, wound closure, and suturing require concentration and practice. The development of new thought patterns regarding surgical esthetics is necessary, and attention must be paid to micro-anatomy, tissue manipulation, and surgical craftsmanship.

Effective periodontal microsurgery allows the operator to consistently achieve clinical results that were once thought to be unlikely.

HAND CONTROL

Physiologic Tremor

For a basic understanding of the fine finger movements necessary with the use of microscopic magnification, some important aspects of hand function must be reviewed. Finger movements controlled by the long flexor and extensor muscles that move our fingers are relatively crude. Thus, active finger extensions, or flexions, are likely to be relatively crude. However, when the wrist is stabilized by resting on a flat surface, angled in a dorsiflexion position at approximately 20 degrees, more accurate, finely controlled finger movement can be accomplished because of the reduction in muscle tremor provided by this "platform."^{2,5}

Physiologic tremor is the uncontrolled movement arising from both the intended and unintended actions of our bodies. Awareness of its effect is magnified by visual enhancement. During microsurgery, physiologic tremor manifests as a naturally occurring unwanted hand and finger movement.⁴ To minimize tremors, a microsurgeon must have a relaxed state of mind, good body comfort

and posture, a well-supported hand, and a stable instrument-holding position. Attitude is also very important.⁵ Mental focus and patience during the procedure are important factors in maintaining precise motor control skills.

Physiologic tremor is usually associated with tension generated by the postural control "antigravity" muscles.⁶ Since these muscles are a major cause of tremor, a relaxed and proper seating posture is essential. A microsurgeon's chair is required to provide proper arm and hand support. The surgeon must be seated upright with the legs extending forward and with both feet flat on the floor so that the calf of each leg forms a right angle to the thigh. Support of the ulnar surface of the forearm and wrist is necessary to control or reduce tremor. The surgeon's head should be held in a comfortable upright position (Fig 1). Proper ergonomics can help to prevent neck and back injuries resulting from poor chairside habits. During a surgical procedure, patient and chair position must be adjusted to the surgeon and the microscope.

In microsurgery, the hand should either directly or indirectly rest on an immovable surface or unwanted movements will occur. Only the fingertips move. All movements should be efficient and economical, and should be made with a unity of effort toward purposeful, deliberate motions. There are several factors that can influence a surgeon's physiologic tremor, including anxiety, recent exercise, alcohol, smoking, caffeine, heavy meals, hypoglycemia, and medication usage.

Hand Grips

Basic hand skills in the United States have been associated with and thought of as an extension of penmanship. With the increased use of keyboards for computers and text messaging on mobile devices, educational curricula no longer stress penmanship. This may play a role in

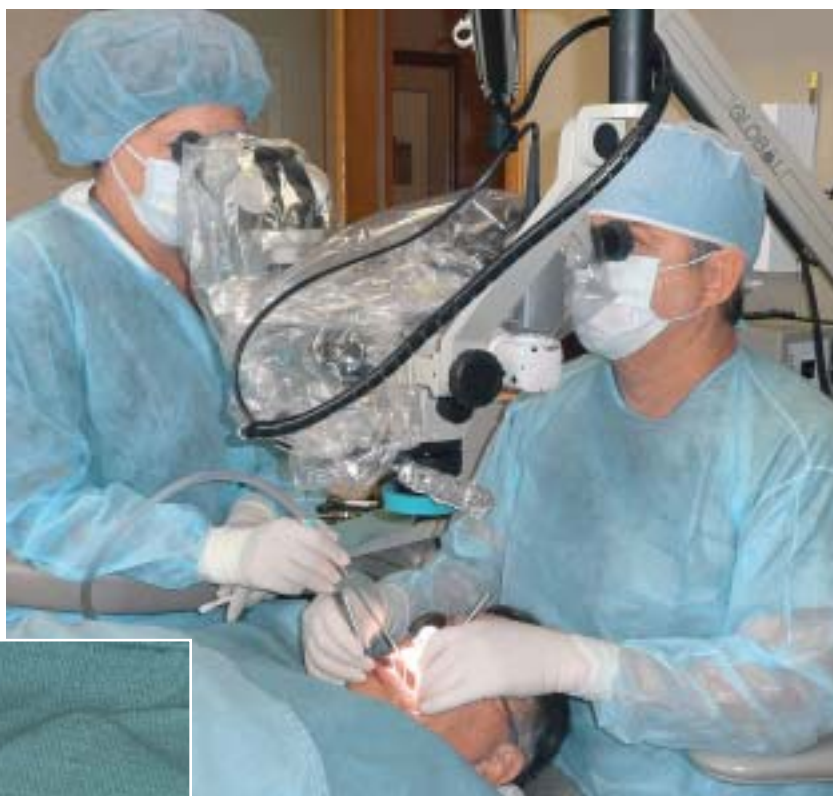

Fig 1 Clinician seated at microscope with correct posture and arms supported.

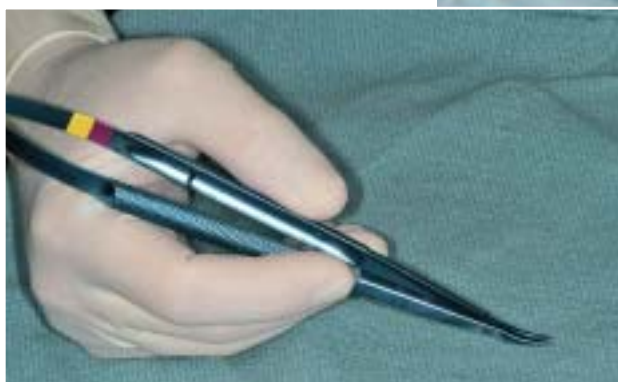

Fig 2 Precision grip.

the lack of basic hand skills in the “writing” or penmanship position. The acquisition of poor ergonomic habits prior to and during dental education may increase the time it takes for postgraduate residents to become proficient in microsurgery.

The most commonly used precision grip in microsurgery is the pen grip or internal precision grip, which gives greater stability than any other hand grip.^{2,7} In the three-digit grip, an instrument is held exactly as a pen would be held when writing. The thumb and index and middle fingers are used as a tripod (Fig 2). The forearm should be slightly supine, positioning the knuckles away from you, so that the ulnar border of your hand, wrist, and the elbow are all well supported, allowing the weight of the hand to be on

the ulnar border. The middle finger should rest firmly and directly on either the working surface supporting the hand or indirectly on the ring finger. With the tripod formed by the fingers in the pen grip, the middle finger holds the instrument. The thumb and index finger are arranged on the instrument into contact with the underlying middle finger. When an instrument is held with the internal precision grip, the instrument can be opened and closed with very fine control. Any tremor resulting from the thumb or index finger is minimized by the contact with the supported, steady middle finger. Using the pen grip, the flexor and extensor muscles of the hand are relaxed, resisting fatigue, while the intrinsic muscles that rotate the hand are well postured, resulting in the most

accurate motion of which the hand is capable (eg, rotational movement^{8,9}). It is best to start with the pen grip until basic manipulations are mastered and more freehand positions can be initiated. Regardless of the surgeon’s postural position, when the hands are in an unsupported position or the operator’s breath is held, the whole body becomes rigid when trying to perform precision tasks. Accurate, exact hand movements with instruments of the correct length and design along with precision hand grips are crucial to good microsurgical results.

The microsurgeon’s position relative to the patient is an important consideration. When picturing an imaginary clock laying flat on the table in front of you, with the patient’s head in the 12 o’clock position in

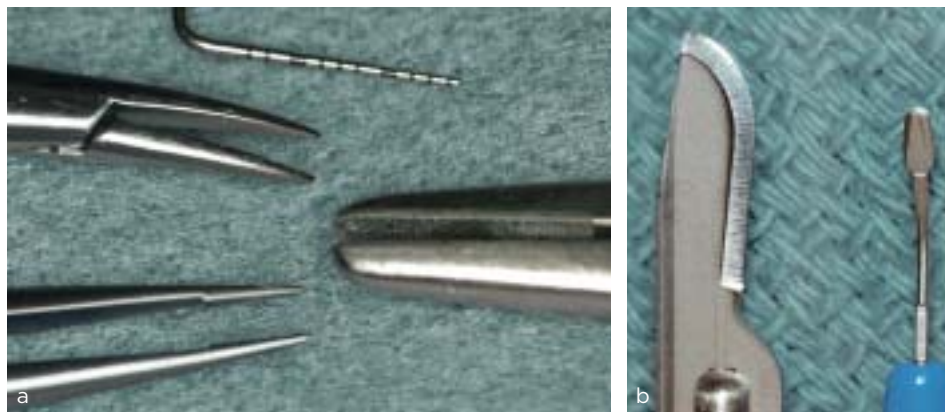

Fig 3a Relative size of microsurgical needle holders and pick-ups and a standard needle holder.

Fig 3b No. 15 scalpel blade and mini-crescent microsurgical blade.

front of and perpendicular to your chest, the most precise rotary suturing movement for a right-handed person is from the 2 o'clock to the 7 o'clock position, while the most precise movement for left-handed people is from the 10 o'clock to the 4 o'clock position.

Once command in suturing from the 2 o'clock to 7 o'clock position is gained from repeated practice, proficiency of the 10 to 4 position is necessary. Persistent practice of alternative positions around the entire 360-degree axis ultimately results in mastery of surgical skills necessary to render successful microsurgical treatment in all areas of the mouth.

MICROSURGICAL INSTRUMENTS

With microscopic magnification and the use of microsurgical instruments, tissue trauma and bleeding can be minimized. For high-precision movement, microsurgical instruments must be approximately 15 cm in length. For an average-sized hand, this provides adequate length for an instrument held in a pen grip to rest in the web between the thumb and index finger. There are also subtle design features for these instruments that help accomplish the desired surgical results. Instruments should be circular in cross section to allow for a smooth rotation movement. The working tips of microsurgical

instruments are much smaller than those of regular instruments (Figs 3a and 3b). To provide consistent manipulation of tissues, needles, and sutures, most microsurgical instruments are manufactured under magnification to high tolerances. Needle holders and tissue forceps are made of titanium. Properly cared for, such instruments are resistant to distortion from repeated use and sterilization, are nonmagnetized, and are lighter than surgical stainless steel instruments. Shorter instruments, as well as instruments with a rectangular cross-sectional design, do not allow as precise manipulation and therefore are not ideal for microsurgery.

MAGNIFICATION METHODS

Dentists have a wide range of simple and complex magnifying systems that are available, including three types of magnification loupes¹⁰ and the operating microscope.¹¹ Both types of optical magnification have advantages and limitations. The mode of magnification used is often based on the task to be accomplished and the operator's experience level. Whether or not more magnification is better must be weighed against the size of the viewing field and the depth of focus that occurs as magnification is increased. Increases in magnification require proportionate increases in field illumination.^{2,12}

Loupes

Loupes are the most common form of magnification used in dentistry. Fundamentally, loupes are two monocular microscopes with side-by-side lenses that are angled to focus on an object. The magnified image that is formed by the convergent lens system has stereoscopic properties. The disadvantage of loupes is that the eyes must converge to view an image, which can result in eyestrain, fatigue, and even vision changes with prolonged use of poorly fitted loupes.¹³ Only two types of loupes, compound and prism, are commonly used in dentistry today. Both types employ convergent optics, but may differ widely in design and lens construction.

Compound loupes. To gain refracting power, magnification, working distance, and depth of field, compound loupes use converging multiple lenses with intervening air spaces. Such lenses can be adjusted to clinical needs without excessive increase in size or weight. Compound lenses can be achromatic. The lenses consist of two glass pieces bonded together with clear resin. The specific density of each piece counteracts the chromatic aberration of the adjacent piece, making such lenses a desired feature by dentists. Compound loupes are commonly mounted in or on eyeglasses.

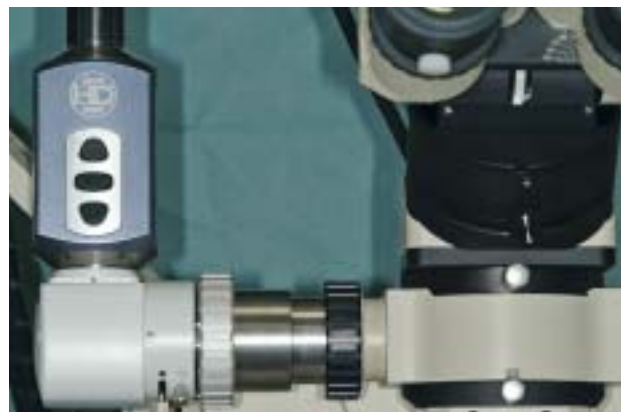Prism loupes. Prism loupes contain Schmidt or rooftop prisms that lengthen the light path through a series of mirror reflections within the loupes, virtually folding the light so that the barrel of the loupe can be shortened. These loupes are the most optically advanced type of loupe magnification presently obtainable. Prism loupes produce better magnification, wider depths of field, longer working distances, and larger fields of view than other types of loupes. The barrels of prism loupes are short enough to be mounted on either eyeglasses or a headband, but at magnifications of 3.0 diameters or greater the increased weight often results in headband-mounted loupes being more comfortable and stable than those mounted on glasses. To obtain better optical characteristics and magnification than those achievable with prism loupes requires the use of the surgical microscope.

Loupe magnification. Loupes with magnifications ranging from 1.5 \times to 10 \times can be purchased from a number of vendors. Those with magnifications of less than 4 \times are usually inadequate for microdentistry or periodontal microsurgery. For most periodontal procedures, loupes of 4 \times to 5 \times provide increased visual acuity with an effective combination of magnification, field size, and depth of field. Loupes of 4.5 \times magnification or greater need to be thoroughly evaluated before purchasing, as their depth of focus and narrow field size can make them awkward to use.

Operating Microscope

For the greatest flexibility and comfort in optical magnification, the properly equipped operating microscope is vastly superior to magnifying loupes. With instruction and practice, the operating microscope can be simple to use. It is, however, much more expensive and initially more difficult to use. Operating microscopes combine the magnification of loupes with a magnification changer and a binocular viewing system. The parallel

Fig 4 HD video camera mount.



binoculars protect against eyestrain and fatigue. Operating microscopes incorporate fully coated optics and achromatic lenses with high-resolution and high-contrast stereoscopic vision. Operating microscopes are designed on Galilean principles.

When using the microscope, there must be an adequate working distance between the microscope and the object being viewed for instruments to be used. For use in the various areas of the mouth, the microscope must have extensive horizontal and vertical maneuverability, whether it is mounted to a wall, ceiling, or floor stand. The addition of inclinable binocular eyepieces gives a microscope great improvement in maneuverability. Surgical microscopes use coaxial fiber-optic illumination. This type of light produces an adjustable, bright, uniformly illuminated, shadow-free, circular spot of light that is parallel to the optical viewing axis.

Loupes Versus Operating Microscope

There are a few advantages and disadvantages to each system.^{14,15} Loupes are less expensive and initially easier to use. They are also less cumbersome in the operating field and less likely to breach a clean operating field. Both loupes and the microscope improve visual acuity and ergonomic comfort and efficiency by increasing the working distance. When dentists assume a working distance of 13 inches or less to the

patient without magnification or with ill-fitted loupes, a multitude of eye, neck, shoulder, and back problems become increasingly evident with age. Such problems may be reduced or eliminated by using magnification. A 6- to 8-inch increase in normal working distance has been shown to vastly improve postural ergonomics and reduce eyestrain in industrial workers.¹⁶

The advantages of the operating microscope include its versatility due to an extended range of variable magnification from 2.5 \times to 20 \times and to excellent coaxial fiber-optic, shadow-free illumination. An additional advantage is the availability of numerous accessories for digital still and video image case documentation (Fig 4). The greatest advantage, however, is increased operator eye comfort due to the parallel viewing optics provided by the Galilean system. Conversely, the limitations of loupes include fixed magnification and the potential need for additional light for magnification levels of 4.0 \times or greater. Loupes with large fields of view have brighter illumination and brighter images than those with narrower fields of view. Brightness and illumination can also be improved by increasing the working distance. When using loupes, each surface refraction that occurs through the lens results in a 4% loss of transmitted light unless antireflective coatings are used. Antireflective coatings allow the lens to transmit light more

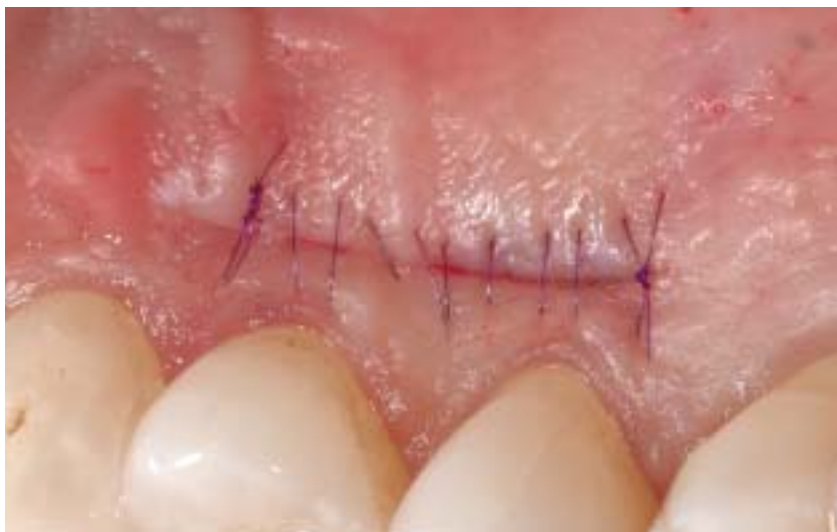

Fig 5 Microsurgical palatal donor site closure. (Courtesy of Dr Adriana McGregor.)

effectively. Compound and prism loupes without antireflective coatings could have as much as a 50% reduction in brightness.

After using magnification loupes and the surgical microscopes for over a decade and a half, the authors find that the use of the microscope offers many advantages over loupes. The difference is similar to comparing the use of a belt-driven handpiece versus an electric motor handpiece under a multitude of conditions. Both types of handpiece can be used to prepare teeth for restorative work or for surgical procedures, but the latter is much more versatile and efficient. Likewise, both loupes and the operating microscope allow clinicians to perform tasks not possible without improved visual acuity; however, loupes cannot compare to the comfort, versatility, illumination, and visual acuity offered by the microscope.

Although magnification makes microsurgery possible, there are also drawbacks, including: (1) a restricted area of vision and loss of depth of field as magnification increases, (2) loss of visual reference points, (3) extra time needed to develop an experienced team approach for planning and practice to avoid errors in positioning instruments and placement of sutures, (4) accentuated physiologic tremor that must be controlled for fine movements, and (5) a

steep learning curve. Different magnifications are appropriate for various stages of a procedure. For example, high magnification is used for passing a suture needle through tissue, and lower power is used to pull the suture through the tissue so that you can see the end of the suture as it approaches. Common sense dictates that it is important to use the lowest magnification level possible to accomplish each stage of the procedure being performed.

SUTURES

One of the three basic premises of microsurgery is attention to passive wound closure.⁵ The desired result is exact primary apposition of the wound edge. Ideally, the incisions should be almost invisible and closed with precisely placed, small sutures with minimal tissue damage and no bleeding (Fig 5).

With all of the surgical subspecialties, suture materials and techniques have evolved to the point that sutures are designed and developed for specific procedures. What has been developed for medicine is subsequently used in dentistry. The criteria necessary for successful use of suture materials are dependent on the surgical procedure to be performed and the factors necessary

to successfully close the wound in a manner that promotes optimum healing. To utilize microsurgical principles requires knowledge of the tissue-healing characteristics and biologic characteristics of the various suture materials being used. A suture material must be selected that will retain its strength until the wound heals sufficiently to withstand stress on its own. An ideal suture material is sterile, easy to handle, minimally reactive in tissue, resistant to shrinkage in tissues, and capable of holding securely when knotted without fraying or cutting. Ideally, the needle and the suture material should be the same size. The only variable in an ideal suture material is its size and tensile strength and the size and type of needle swaged onto the material.

Essentially all sutures used in dentistry today are swaged, making the suture and the needle a continuous single unit. Size denotes the diameter of the suture material, and accepted surgical protocol is to use the smallest diameter suture necessary to adequately hold the wound tissue together. The smaller the suture material and needle used to pass through the tissue, the less trauma will result.

Suture size is stated numerically, as in 3-0 or 7-0. The larger the number of zeros, the smaller the diameter of the suture. The smaller the size of



Fig 6a Different-sized sutures. (top) 4-0 Vicryl on a FS-2 cutting needle; (bottom) 6-0 polypropylene on a KV-11 taper cutting needle.

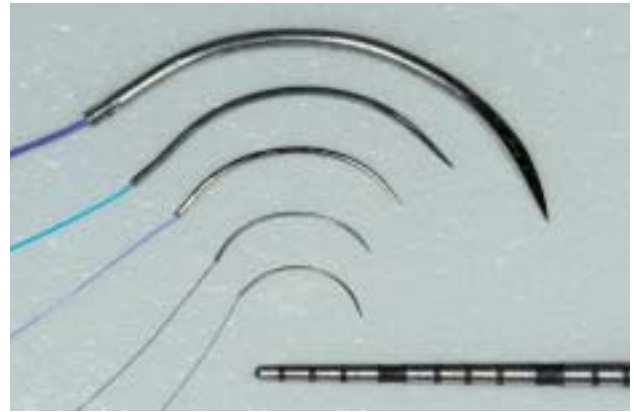


Fig 6b (top to bottom) 4-0 Vicryl, 6-0 polypropylene, 7-0 PDS-II, 8-0 nylon, 10-0 nylon.




Fig 6c (left to right) 8-0 nylon, 7-0 polypropylene, 6-0 polypropylene, 4-0 Vicryl.




Fig 7 Suture needle anatomy: 1, point; 2, body; 3, attachment.

the suture, the less tensile strength the suture will have depending on the procedure being performed. Most periodontal microsurgical suturing is done with sutures ranging in size from 6-0 to 9-0 (Figs 6a to 6c). The most common suture used in macroscopic dentistry is a 4-0 suture on a three-eighths circle FS-2 reverse cutting needle.

Sutures are also classified according to the composition of the suture strand (eg, monofilament, braided multifilament), surface characteristics (coated or uncoated), and absorption properties (absorbable or non-absorbable).

Suture Needle Anatomy

Every surgical needle has three distinct elements: the point, the body, and the attachment (Fig 7).¹⁸

The point extends from the tip of the needle to the maximum cross section of the body of the needle. It is designed to penetrate specific types of tissue. There are several types of cutting needles, taper point needles, taper cut surgical needles, and blunt point needles. Reverse cutting needles are frequently used in dentistry where minimal trauma and early regeneration of tissue is desired. Since the third cutting edge of the needle is located on the outer convex curvature, the danger of a tissue cutout is reduced. The hole left by the reverse cutting needle leaves a wide wall of tissue against which the suture is tied. Taper point needles or round needles pierce and spread the tissue without cutting it. They are used when the smallest possible puncture hole and minimal tissue cut-

ting is desired. The taper cut surgical needle combines the reverse cutting edge tip and taper point, with the three cutting edges extending approximately 1/32 inch back from the tip before blending into the round taper body. A taper cut needle is used for suturing through dense fibrous connective tissue and periosteum. Blunt point needles are used to dissect through friable tissues rather than cut through them.

The body of the needle comprises slightly more than the middle third of the needle. This is the portion of the needle that is grasped by the needle holder during suturing. The size of the body should be as close as possible to the diameter of the suture material in microsurgical procedures.

The attachment (swaged end) is a method of attaching the needle and

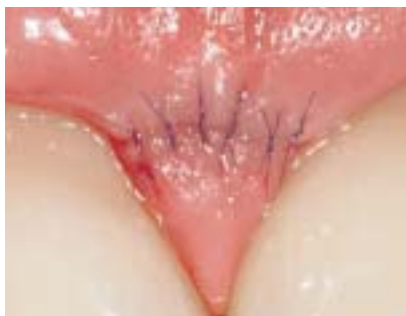

Fig 8a Proper wound coaptation and suturing.

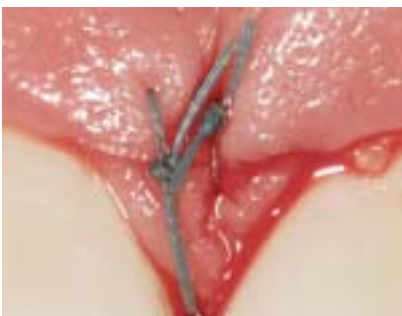

Fig 8b Improper wound coaptation and suturing.

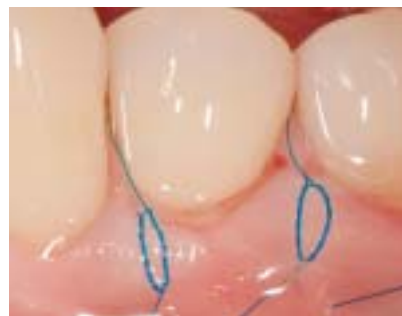

Fig 9 Properly tied microsurgical reef knots.

suture together in a continuous unit that is convenient to use and minimizes tissue trauma.

Selection of an appropriate needle is dependent on where and how the suture will be used. Factors to consider in the selection of a suture needle include:

- **Chord length:** the straight-line distance from the point of a curved needle to the swage.
- **Needle length:** the distance measured along the radius of the needle from the point to end.
- **Radius:** the distance from the center of the circle to the body of the needle if the curvature of the needle were to make a full circle. In dentistry, the needle radius most commonly used is the three-eighths circle, but the one-fourth circle and one-half circle are also used. Such shapes require less space for maneuvering than a straight needle.
- **Diameter:** the thickness or gauge of the needle wire.

Microsurgery uses needles of a fine-gauge material that are small to very small. Surgical needles are designed for maximum needle holder stability. Needle holder performance has a significant impact on the entire suturing procedure. The surgeon must have the utmost control of the needle sitting in the holder without the needle wobbling as it is passed through the tissue. Therefore, the needle holder must be appropriately sized for the needle and suture selected.

Suture Geometry

Suturing techniques are completely different in macrosurgery and microsurgery. With magnification, a surgeon is able to scrutinize discrepancies that occur with macrosurgery and embrace a more efficient approach to wound closure. The microsurgical approach is dependent on careful, atraumatic entry incisions and dissection to allow passive wound closure. This is followed by wound closure using the fundamental geometric approach, with the goal of primary and passive wound closure.

The geometry of microsurgical suturing consists of the following points¹⁹:

1. Needle angle of entry and exit of slightly less than 90 degrees
2. Suture bite size of approximately 1.5 times the tissue thickness
3. Equal bite sizes (symmetry) on both sides of the wound
4. Needle passage perpendicular to the wound

Gentle coaptation of a wound using the above geometric standards prevents either incomplete wound closure or overlapping of the wound. The results of geometric, perpendicular suturing are uncomplicated wound closure, as compared to when sutures pass across an incision line at an oblique or an acute angle, resulting in dead spaces or microgaps with longer postoperative healing (Figs 8a and 8b).

Knot Tying

Suturing is a critical factor in periodontal treatment success. Suturing techniques and knot tying, however, occupy only minimal time in dental education curricula, and are consequently learned according to the old phrase “watch one, do one, teach one.”

Macroscopic knot tying is done with full visualization of the hands. The needle holder is held in the dominant hand and the gloved fingertips of the nondominant hand are used to help place and tie sutures using proprioception (ie, the unconscious perception of movement and spatial orientation arising from within the body).

Knot tying using the microscope is done using instrument ties, with a microsurgical needle holder in the dominant hand and a microsurgical tissue pick-up in the nondominant hand. Only the working tips of the instruments are visible in the microscopic field. Microsurgery is therefore done by visual reference only, as the breaking force of microsutures is often less than the human threshold of touch. Microinjury to tissues also occurs below the proprioceptive ability of the human hand. Well-tied microsurgical suture knots are stable and resist loosening, even under functional loads.²⁰ The art of microscopically tying a good surgeon's knot, a reef knot, or a cinching knot can only be mastered with repeated laboratory practice under the microscope (Fig 9).²¹

Fig 10 Microsurgery blades compared to a 15C scalpel blade.



PERIODONTAL MICROSURGERY

Periodontal microsurgery is generally associated with esthetic periodontal plastic surgery, because of the intricate detail and small scale of the work made possible by the surgical microscope. Microsurgical principles also have application in more extensive periodontal surgical procedures, including resective procedures, combined resective/periodontal microsurgery and regenerative procedures, extractions and ridge preservation procedures, sinus augmentations and repairs, biopsies, and larger soft tissue transfers. Such procedures utilize microsurgical instruments to make incisions that are just long enough to afford access for operating space and exposure. Incisions should be clean and precise, with as little trauma as possible. Appropriately designed and sized microsurgical instruments produce minimal tissue trauma and promote healing (Fig 10). Tissue should be handled very gently and as little as possible. Retraction should be done carefully to avoid excess pressure, since tissue tension can alter the local physiologic state of the wound. Achieving a bloodless field should

be a goal to avoid compromising the surgeon's field of view. Controlling homeostasis before wound closure prevents the formation of postoperative hematomas. By adequately closing a wound site with passive closure, dead space in the wound is eliminated.

Many of the procedures mentioned above use 5-0 to 7-0 sutures. This is necessary because the chord length of the suture needle must be long enough to be passed inferior to the contact points of the teeth.

Periodontal Plastic Microsurgery

The term mucogingival surgery was introduced into the periodontal literature in the 1950s. The current terminology, periodontal plastic surgery, is defined as surgical procedures performed to correct or eliminate anatomic, developmental, or traumatic deformities of the gingiva or alveolar mucosa.²³ Periodontal plastic surgery is an integral aspect of periodontal education and practice. Knowledge of medical microsurgery offers a view as to what esthetic needs can be realistically achieved while treating periodontal problems. Improvement in esthetics is a major indication for periodontal plastic surgery.

Esthetic Surgical Procedures

When attempting to restore gingival esthetics, several periodontal plastic surgery procedures are helpful, including pedicle soft tissue grafts and free soft tissue grafts. The direction of transfer of the pedicle graft determines whether it is divided into rotational flaps (eg, laterally sliding flap, papilla flap, or double papilla flap) or advanced flaps without rotation or lateral movement (eg, coronally positioned flap). The pedicle soft tissue graft combined with the use of a membrane barrier, according to the principles of guided tissue regeneration, is also used as a treatment for root coverage. When using a guided tissue regeneration barrier, it is critical to maintain a space between the barrier membrane and the root surface for tissue regeneration.

To correct small areas of recession without invasive major flaps, careful dissection and suturing can sometimes be used to place a graft (Figs 11 and 12). Free soft tissue grafts can be performed as a full-thickness epithelialized soft tissue graft or a subepithelial connective tissue graft, with the donor tissue for both procedures usually taken from the palate. A subepithelial connective tissue graft is normally harvested from the palate by

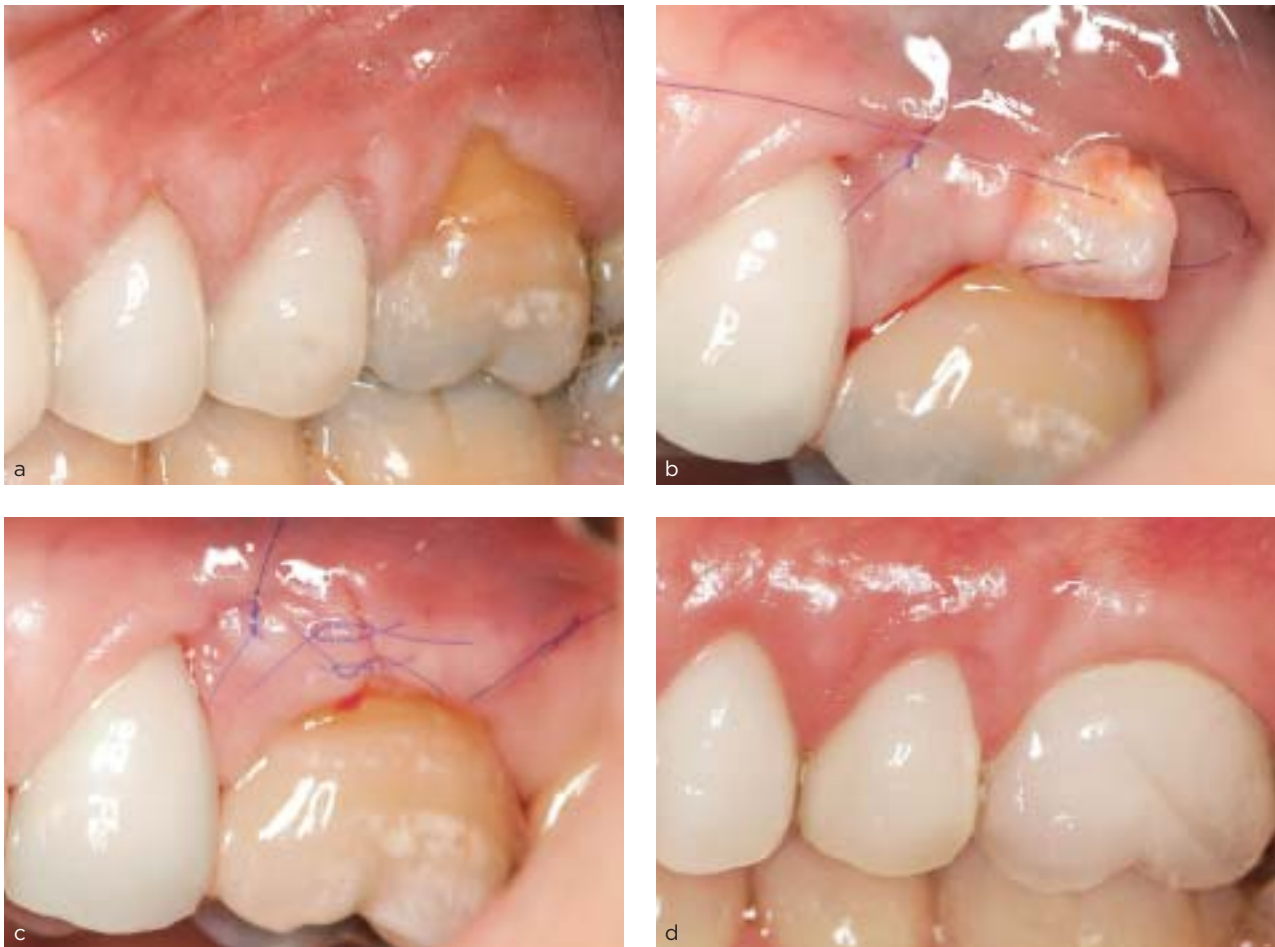

Fig 11 Preoperative (a), graft being placed (b), sutured graft (c), and postoperative (d) views of connective tissue graft. (Courtesy of Dr. Scott Kissel.)

a “trap door” approach,^{24,25} which is minimally invasive and heals rapidly.

Microsurgically transferring donor tissue removed from one area of the mouth to a new microsurgically prepared recipient site allows for correction of gingival esthetic problems.²⁶ Survival of the grafted tissue, whether the procedure is done macroscopically or microsurgically, is dependent on the recipient site having a blood supply to restore circulation to the transferred tissue.²⁷ Attempting to graft over avascular root surfaces is a unique challenge in periodontics, but it has become more predictable, depending on the defect,

with both macrosurgery and microsurgery (Fig 13). Autologous grafts (ie, tissue borrowed from one area and then transferred to another area within the same individual²⁸), homologous grafts (ie, freeze-dried human dermal allografts from different individuals of the same species), and heterologous grafts (ie, bovine collagen membranes from donors of a different species) can be used in root coverage procedures. Complete root coverage of gingival recession is predictably achievable in Miller Class I and Class II defects. Only partial coverage may be expected in Class III or Class IV²⁹ defects. Root coverage

grafting, in the hands of the authors, is most predictable using autologous grafts because they revascularize quickly. The two most reliable root coverage techniques are the full-thickness gingival graft and subepithelial connective tissue graft. Full-thickness gingival grafts do not offer as good a color match as subepithelial connective tissue grafts and produce a less natural appearing result, but can usually restore narrow recession defects.³⁰ Wide recession defects can more predictably be restored by subepithelial connective tissue grafts.

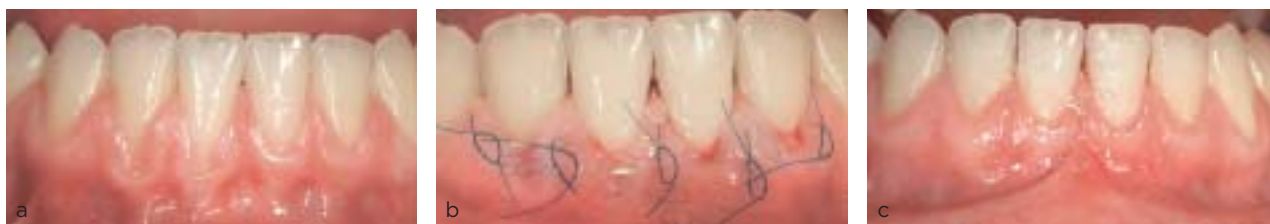

Fig 12 Preoperative (a), sutured connective tissue graft (b), and postoperative (c) views typical of other microsurgical procedures. (Courtesy of Dr J. David Cross.)

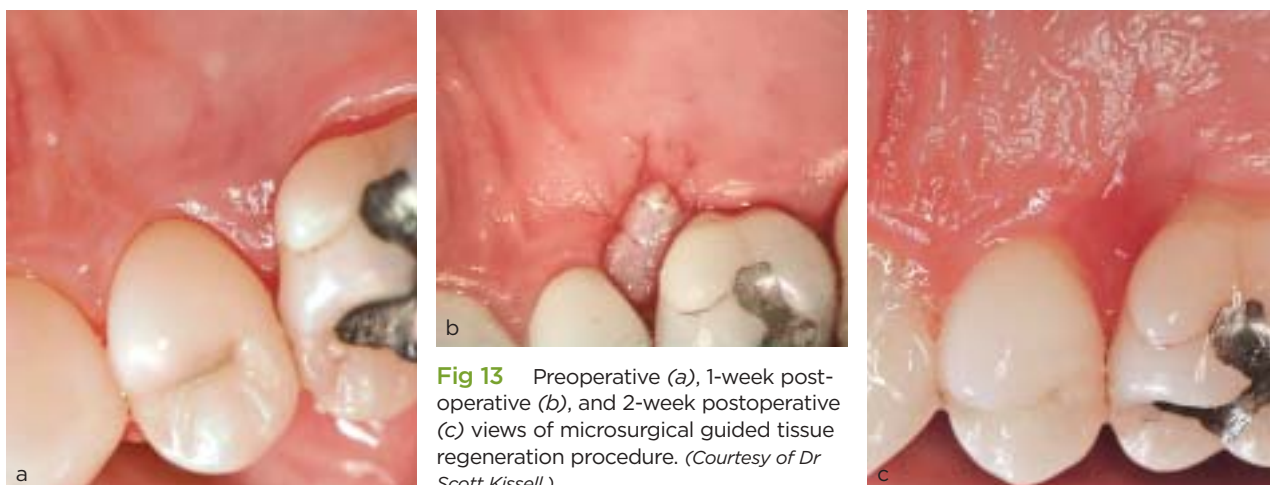

Fig 13 Preoperative (a), 1-week postoperative (b), and 2-week postoperative (c) views of microsurgical guided tissue regeneration procedure. (Courtesy of Dr Scott Kissell.)

Root Surface Conditioning

Since root surface preparation addresses how the soft tissue attaches to the root of the tooth in root coverage surgery, it is of the utmost importance; however, it is not within the scope of this article to discuss in detail. Suffice it to say, in an attempt to get new periodontal ligament attachment of a graft to the tooth with new cementum and Sharpey's fibers, several methods of root preparation have been suggested,³¹⁻³³ including mechanical root preparation, chemical root preparation, and biologic root preparation. The outcomes of some methods are

based on histologic evidence and others on empirical observation, but all are important for successful root coverage.

CONCLUSIONS

Periodontal microsurgery has many applications and benefits. As health care professionals and the public become familiar with the benefits of microsurgery, applications of this philosophy in periodontics will likely become a treatment standard. Microsurgical periodontics requires a different practitioner mindset. It is technique-sensitive and more demanding

than periodontal macro-surgery, but it results in more rapid healing because it is less invasive and less traumatic. The improved visual acuity and ergonomics provide significant advantages to those who take the time to become proficient in microsurgical principles and procedures. The operating microscope allows the surgeon to practice enhanced, precise, delicate surgical procedures that have important healing processes and outcomes for patients. Periodontal microsurgery and periodontal plastic microscopic surgery provide a natural evolution in the progression of periodontics.

REFERENCES

- Daniel RK. Microsurgery: Through the looking glass. *N Engl J Med* 1979;300:1251–1257.
- Barraquer JI. The history of microsurgery in ocular surgery. *J Microsurg* 1980;1:288–299.
- Tibbetts LS, Shanelec D. Periodontal microsurgery. *Dent Clin North Am* 1998;42:339–359.
- Serafin D. Microsurgery: Past, present and future. *Plast Reconstr Surg* 1980;66:781–785.
- Acland R. *Practice Manual for Microvascular Surgery*, ed 2. St Louis: CV Mosby, 1989.
- Chang T, Zhu S, Wang Z. *Microsurgical Principles, Techniques and Applications*. Singapore: World Scientific Publishing, 1986.
- Bunke H, Chater N, Szabo Z. *The Manual of Microvascular Surgery*. San Francisco: Ralph K. Daves Medical Center, 1975.
- Klopper P, Muller JH, Van Hattum AH. *Microsurgery and Wound Healing*. Amsterdam: Excerpta Medica, 1979.
- Lee S. *Manual of Microsurgery*. Boca Raton, FL: CRC Press, 1985.
- Owen ER. Practical microsurgery. I. A choice of optical aids. *Med J Aust* 1971;1:244–246.
- Daniel RK, Terzis JK. The operating microscope. In: *Reconstructive Microsurgery*. Boston: Little Brown and Company, 1977:3–23.
- Hoerenz P. The Operating microscope: 1. Optical principles, illumination, systems, and support systems. *J Microsurg* 1980;1:243–245.
- Shanelec DA. Optical principles of loupes. *Calif Dent Assoc J* 1992;20:25–32.
- Hedon P, Wineman M, Winston RNI. Loupes or microscope for tubal ligation anastomosis. *Fertil Steril* 1980;34:264–268.
- Rock JA, Bergquist CA, Kimball AW Jr, Zacur HA, King TM. Comparison of the operating microscope and loupes for microsurgical tubal anastomosis: A randomized clinical trial. *Fertil Steril* 1984;41:229–232.
- Schmide H. Untersuchungen über die Abhängigkeit der Bewegungsgenauigkeit im Raum von der Körperstellung, Forschungsbericht No. 941 aus dem Kultusministerium des Landes Nordrhein-Westfalen. Cologne: Westdeutscher, 1961.
- Shanelec D. Principles of periodontal plastic surgery. In: Rose L, Mealey B, Genco R, Cohen D (eds). *Periodontics: Medicine, Surgery, and Implants*. St Louis: Mosby, 2004.
- Wound Closure Manual. Somerville, NJ: Ethicon, 1994.
- Price PB. Stress, strain and sutures. *Ann Surg* 1948;128:408–421.
- Mehdorn M, Muller G. *Microsurgical exercises: Basic Techniques, Anastomoses, Refertilization, Transplantation*. Stuttgart: Thieme Medical, 1989.
- Thacker JG, Rodeheaver G, Moore JW, et al. Mechanical performance of surgical sutures. *Am J Surg* 1975;130:374–380.
- Tibbetts L, Shanelec D. A review of the principles and practice of periodontal microsurgery. *Tex Dent J* 2007;124:188–204.
- Wennström JL. Mucogingival therapy. *Ann Periodontol* 1996;1:671–706.
- Edel A. Clinical evaluation of free connective tissue grafts used to increase the width of keratinized gingiva. *J Clin Periodontol* 1974;1:185–196.
- Langer B, Langer L. Subepithelial connective tissue graft. A bilaminar reconstructive procedure for the coverage of denuded root surfaces. *J Periodontol* 1985;56:715–720.
- Riediger D, Ehrenfeld M. *Microsurgical Tissue Transplantation*. Stuttgart: Quintessence, 1989.
- Gordon HP, Sullivan HC, Atkins JH. Free autogenous gingival grafts. II. Supplemental findings—Histology of the graft site. *Periodontics* 1968;6:130–133.
- Miller PD Jr: Root coverage using a free soft tissue autograft following citric acid application. Part III. A successful and predictable procedure in areas of deep wide recession. *Int J Periodontics Restorative Dent* 1985;5:14–37.
- Miller PD. A classification of marginal tissue recession. *Int J Periodontics Restorative Dent* 1985;5:47–55.
- Sullivan HC, Atkins JH. Free autogenous gingival grafts. I. Principles of successful grafting. *Periodontics* 1968;6:121–129.
- Bower GM, Schallhorn RG, Mellonig JT, et al. Histological evaluation of new attachment apparatus formation in humans. Part I. *J Periodontol* 1989;60:664–674.
- Bowers GM, Schallhorn RG, Mellonig JT, et al. Histological evaluation of new attachment apparatus formation in humans. Part III. *J Periodontol* 1989;60:683–693.
- Cogen RB, Al-Joburi W, Gantt DG, Denys FR. The effects of various root surface treatments on the attachment and growth of human gingival fibroblasts: Histologic and scanning electron microscope evaluation. *J Clin Periodontol* 1984;11:531–539.